



We Treat Kids Better



**USC** University of  
Southern California

# **Anti NMDA Receptor Encephalitis: Brief review and update on pediatric cases**

**Julienne Jacobson MD  
ACLP Annual Meeting 2021**

## ACLP 2021

# Disclosure: Julienne Jacobson, MD

With respect to the following presentation, there has been no relevant (direct or indirect) financial relationship between the party listed above (and/or spouse/partner) and any for-profit company which could be considered a conflict of interest.

# International Encephalitis Consortium 2013 Diagnostic Criteria

- AMS >24H with no alternative cause
- Minor criteria (3 required)
  - Fever within 72H of presentation
  - New onset focal neurologic findings
  - CSF leukocytosis
  - Acute new neuroimaging findings suggestive of encephalitis
  - EEG abnormality consistent with encephalitis

(Irrespective of etiology of encephalitis)

## Diagnostic Criteria for AE

- Subacute onset (less than 3 months)
  - working memory deficits,
  - altered mental status,
  - psychiatric symptoms
- New focal neuro findings (at least 1)
  - seizures not explained by pre-existing disorder,
  - CSF pleocytosis,
  - MRI features of encephalitis
- Reasonable exclusion of alternative causes

## Antibody negative but probable AE

### All 4 of the following

- Rapid progression (<3 mo) working memory deficits (short term memory loss), AMS, psychiatric symptoms
- Exclusion of well defined syndromes of autoimmune encephalitis
- Absence of well defined Ab of AE in serum and CSF
- At least 2 of the following:
  - MRI abnormalities of AE
  - CSF pleocytosis, CSF oligoclonal bands IgG index or both
  - Brain biopsy showing inflammatory infiltrates, excluding other d/o
- Reasonable exclusion of alternative cause

# AE increasingly recognized as common in children

- Consensus criteria that use clinical history and biomarkers to drive diagnosis
- More common cause of encephalitis than infectious causes

## Diagnostic considerations with AE in children

- Working memory issues challenging to ID in younger patients
- Less frequent well defined neurologic sequence
- Sequence of symptom development may differ from adults
- Temporal lobe seizures and cognitive slowing
  - broad differential in children;  
(limbic encephalitis or acquired temporal lobe pathology in adults)

## Distinguishing clinical features

- Prodromal symptoms in >50% children
- Rapid onset of neuropsychiatric symptoms
  - altered LOC, confusion, sleep disturbance, movement disorders, seizures
- Seizures: most common, often predominant feature
  - focal, multi-focal or generalized
- Abnormal movements in >1/3 patients
  - ataxia, chorea, dystonia, myoclonus, tremor
- Some degree of cognitive impairment cardinal symptoms



## Distinguishing clinical features

- Young children may show developmental regression, language loss, speech impairments
- Behavioral changes: repetitive or stereotypical behaviors, irritability, hyperactivity, hypersexuality, insomnia, anger outbursts
- Psychiatric symptoms in >50%
  - Wide ranging from mood swings, mild personality changes to fulminant psychosis
  - New onset psychosis in children <13 yrs rare: medical work-up necessary

## Why do kids present differently?

- Evolving neuronal circuits,
- Neuro-receptor density,
- Myelination of normal development
  
- Children present with multifocal neuropsychiatric symptoms rather than isolated clinical syndromes

## Anti-NMDARE

- Children

- Movement abnormalities
- Agitation
- Insomnia
- Seizures
- Speech deficits
- Ataxia &/or hemiparesis

- Adults

- Memory deficits
- Psychiatric manifestations
- Central hypoventilation
- Stronger tumor association

- 19-year-old previously healthy female; 2 week history of bilateral leg weakness, muscle spasms and difficulties walking, sudden onset, no triggers or identifiable stressors, no loss of bowel or bladder function.
- Presented to OSH when leg weakness worsened; seen by neurology at OSH with normal MRI brain and cervical spine; discharged; presented at our ED 2 days later
- Neurologic exam fluctuates, neuroimaging not concerning, EEG without concerning findings
- Stressors: ongoing anxiety about multiple areas of her life, occasional partial panic attacks; graduated high school this summer, subsequently began working as a full-time caregiver for her brother who has schizophrenia

- ROS:
  - lost 10 pounds recent without dieting; + fatigue, lightheadedness, increased naps during the day and decreased sleep at night (~5-6 hrs since leg weakness started)  
Denied blurry vision, headaches, weakness of upper extremities, skin rashes; no injury to back or legs.
- Past psychiatric history:
  - Reported having depressed mood and SI after sexual assault at age 10 yrs, sx resolved subsequently. No other past psychiatric history.
- PMH: denied
- Social history:
  - Lives with parents and siblings; graduated high school and subsequently began working as a full-time caregiver for her brother who has schizophrenia. SA by family member (adult male family member grabbed her breast at age 10 yrs)

- **Substance Use History:**
  - Monthly cannabis use, occasional EtOH use
- **Mental Status Exam**
  - Alert, awake, oriented
  - Appearance Neatly combed long hair, appears stated age, clean, very thin, no abnormal movements with normal muscle strength and tone
  - Behavior Good cooperation, appropriate rapport, goal directed, intermittent eye contact, participated in discussion
  - Memory: Age appropriate, Grossly intact
  - Attention: Fair
  - Concentration: Good
  - Speech Goal directed, fluid, bilingual, normal prosody
  - **Mood: Guarded, Anxious**
  - Affect: Congruent
  - Associations: Concrete
  - Insight: fair, Judgment: fair, Impulse Control: Good
- **Diagnosis: Psychological factors affecting medical condition, consider FND**
- **Willing to engage in therapy, able to ambulate with PT; discharged with psychology and outpatient PT referrals**

- Readmitted approx. one month later as transfer from OSH
  - Inpatient for 2 weeks due to sudden onset agitation, laughing and screaming inappropriately, not recognizing family members. Speech regressed rapidly, staring off at times,
- MRI and head CT remain unremarkable, EEG with slowing, LP with WBC (8), encephalitis panel not sent
- Admitted and started on Ativan with PRN Haldol; attempted to arrange ECT without success
- ANA + (low titer)
  
- Transferred to our tertiary children's hospital for rheumatology evaluation

- High concern for anti-NMDARE with related catatonia, developed seizures, diagnoses confirmed 2.5 weeks after admission.
- Prior to confirmation immunotherapy initiated;
  - Received IVIG, steroids, PLEX, rituximab
- Catatonia treated with Ativan (up to 26 mg divided TID)
- Seizures and mood lability treated with VPA complicated by related DRESS syndrome, converted to Lamictal.
- Paraneoplastic work-up not concerning
- Agitation treated with clonidine at one point; discontinued due to labile BP
- Treated on inpatient rehab



- Follow-up in neurology clinic 3 months post discharge with persistent cognitive deficits (memory), not consistently following tasks; fatigue with cognitive and physical tasks
- Denied psychosis, sad related to death in family, anxious at times
- Dealing with the recent death of grandfather, unable to access PT/OT as outpatient
- Stable on gabapentin (being weaned) and Keppra

# Symptoms present in clinical case 1

- Children

- Movement abnormalities
- Agitation
- Insomnia
- Seizures
- Speech deficits
- Ataxia &/or hemiparesis

- Adults

- Memory deficits
- Psychiatric manifestations
- Central hypoventilation
- Stronger tumor association

- Previously healthy 5 year old female admitted for possible seizures; MRI brain was normal, EEG captured several events without correlated electrographic changes, neuro exam was inconsistent.
- Family in a serious car accident 2 months prior to presentation; mother described fear of entering cars, hypervigilance while in a car, reenacts the accident during play, concern for nightmares, increased irritability.
- MSE: Playful child, more withdrawn when MVA was discussed
- Post traumatic stress disorder diagnosed, outpatient therapy referrals provided.

- Readmission 2 weeks later:
- Symptom progression with weeks of behavioral changes, recurrent episodes concerning for seizures, unable to ambulate, incontinent and in diapers.
  - COVID + at an OSH about a week before readmission
  - CT brain unremarkable, LP: 4 WBC, 1 RBC, FAME negative; notable also for UTI
  - MRI Brain w/ + w/o Contrast: Focal abnormality in the pulvinar of the right thalamus (thought to be related to the Covid infection, possibly due to vasculitis); no white matter lesions or leptomeningeal enhancement

EEG 12/24/2020: Diffusely slow and disorganized background that is paradoxically worse during awake, diffuse attenuation, worse on the right and worse while awake, Asymmetric sleep spindles, worse on the right, No epileptiform discharges, no seizures

- Exam: Waxy flexibility and intermittent rigidity on neuro exam.
- Started on VPA 70 mg IV Q6H, Ativan 0.5 mg IV Q6H.

- Developed status epilepticus, transferred to ICU, loaded with Keppra, on Versed
- AntiNMDAR encephalitis confirmed; received IVIg, IV and oral steroids, 5 cycles of plasmapheresis, rituximab twice, and tocilizumab for immunotherapy.
- Steady clinical improvement; on inpatient rehab for 3 weeks but returned to acute care due to lethargy (polypharmacy related), regression and continued seropositivity for anti-NMDAR encephalitis
- At the time of discharge: altered mental status, chorea, intermittent tremulousness and twitching, mirthless laughter, and episodes of screaming without cause.
- Tolerated outpatient wean of clonidine and melatonin;
- Very slow gabapentin wean occurring and remains on quetiapine 6.25 mg QD at last outpatient visit

## Anti-NMDARE symptoms clinical case 2

- Children

- Movement abnormalities
- Agitation
- Insomnia
- Seizures
- Speech deficits
- Ataxia &/or hemiparesis

- Adults

- Memory deficits
- Psychiatric manifestations
- Central hypoventilation
- Stronger tumor association

# Autoimmune encephalitis

- Anti NMDA R encephalitis: most common encephalitis cause in kids
  - UK and Australia: a leading cause of antibody mediated autoimmune encephalitis
  - CA encephalitis project: a leading entity among all cases with known etiology
- Anti-NMDAR Ab discovered in 2007

## Clinical phenotype

- Younger children: present with seizures and abnormal movements
- Adults present with psychiatric symptoms
- 50% patients have prodrome of days to weeks
  - fever, malaise, HA and or GI or upper respiratory infection
- Most cases eventually evolve into a similar syndrome
  
- Seizures in 80%: focal or generalized, status reported
- Abnormal EEG in 90-100%: focal or diffuse slowing and/or epileptiform discharges
- *Extreme delta brush* pattern described in up to 30% of adults
  - not pathognomonic; may support dx



## Clinical phenotype

- Hyperkinetic movements frequent in pediatric cases
- Dyskinesias (orofacial common), choreoathetosis, tremor and dystonia
- Autonomic dysfunction occurs later in symptoms progression
  - Hyperthermia, tachycardia, hypertension, urinary incontinence, central hypoventilation, cardiac dysrhythmia in 40% preadolescents, 50% adolescents


## Clinical phenotype

- Brain MRI abnormal in <50% of peds patients
- Nonspecific findings when present include cortical and/or subcortical basal ganglia and infratentorial T2 hyperintensities with or without transient meningeal enhancement
- Extent and location of imaging findings not reliably correlated with clinical course

# Clinical Guidelines for the Diagnosis of Pediatric Autoimmune Encephalitis

Diagnosis of autoimmune encephalitis (AE) in a developing child is challenging because of

- Overlapping clinical presentation with other diseases
- Complexity of normal behaviour changes
- Limited capacity of very young children to describe symptoms

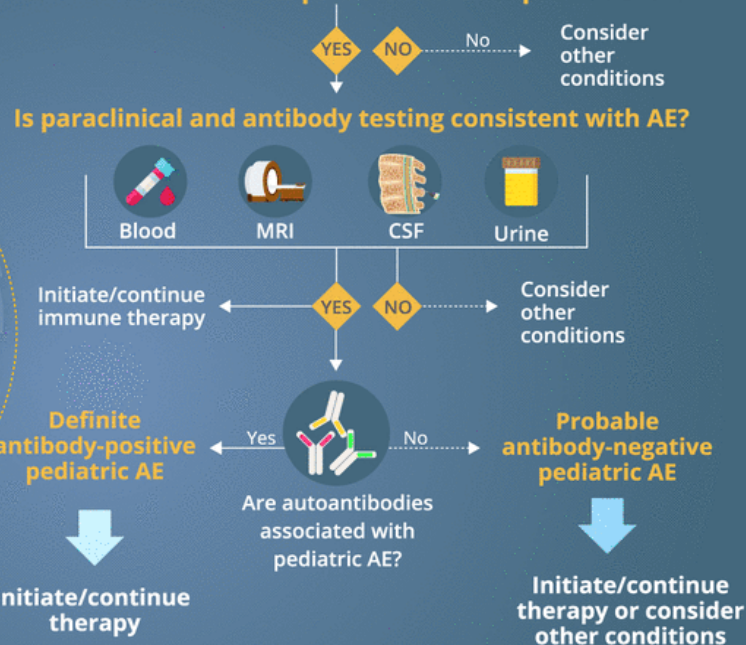


Adult guidelines are not applicable in children due to differences in

- Clinical presentations and paraclinical findings
- Autoantibody profiles

International Autoimmune Encephalitis Working Group has modified existing criteria for adult AE to propose new criteria and an algorithm to guide early diagnosis of pediatric AE

## Patient with clinical presentation of pediatric AE



**Pediatric AE should be diagnosed based on clinical history as well as paraclinical and autoantibody testing**

## Diagnostic Evaluation

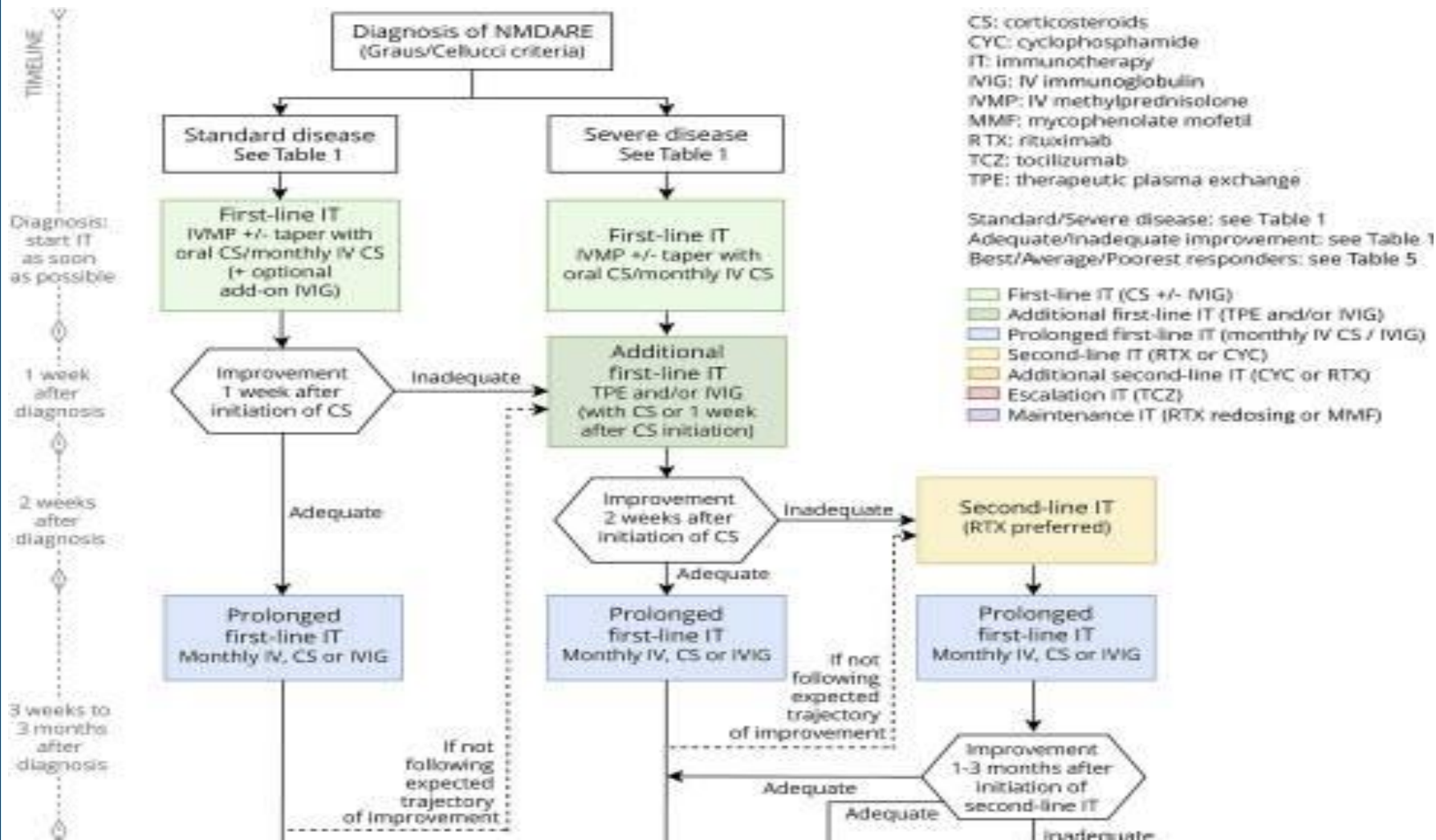
- **Neuroimaging:** Brain MRI with gadolinium (T1, T2, FLAIR and diffusion weighted sequences), consider Spine MRI if neurologic symptoms mediated by spinal cord involvement are present
- **Blood tests:** CBC with differential, ESR, CRP, ferritin, Vit B12, vit D, lactate, thyroid studies, serologic testing for infectious causes, consider ANA and specific antinuclear Abs (Anti ds-DNA, anti-Smith), complement and Ig levels
- **Urine toxicology**
- **LP:** opening pressure, CSF cell counts, lactate oligoclonal bands, neopterin, infectious testing and save 5-10 mL
- **Respiratory testing:** NP swab and mycoplasma PCR
- **EEG:** seizures, epileptiform discharges, changes in background

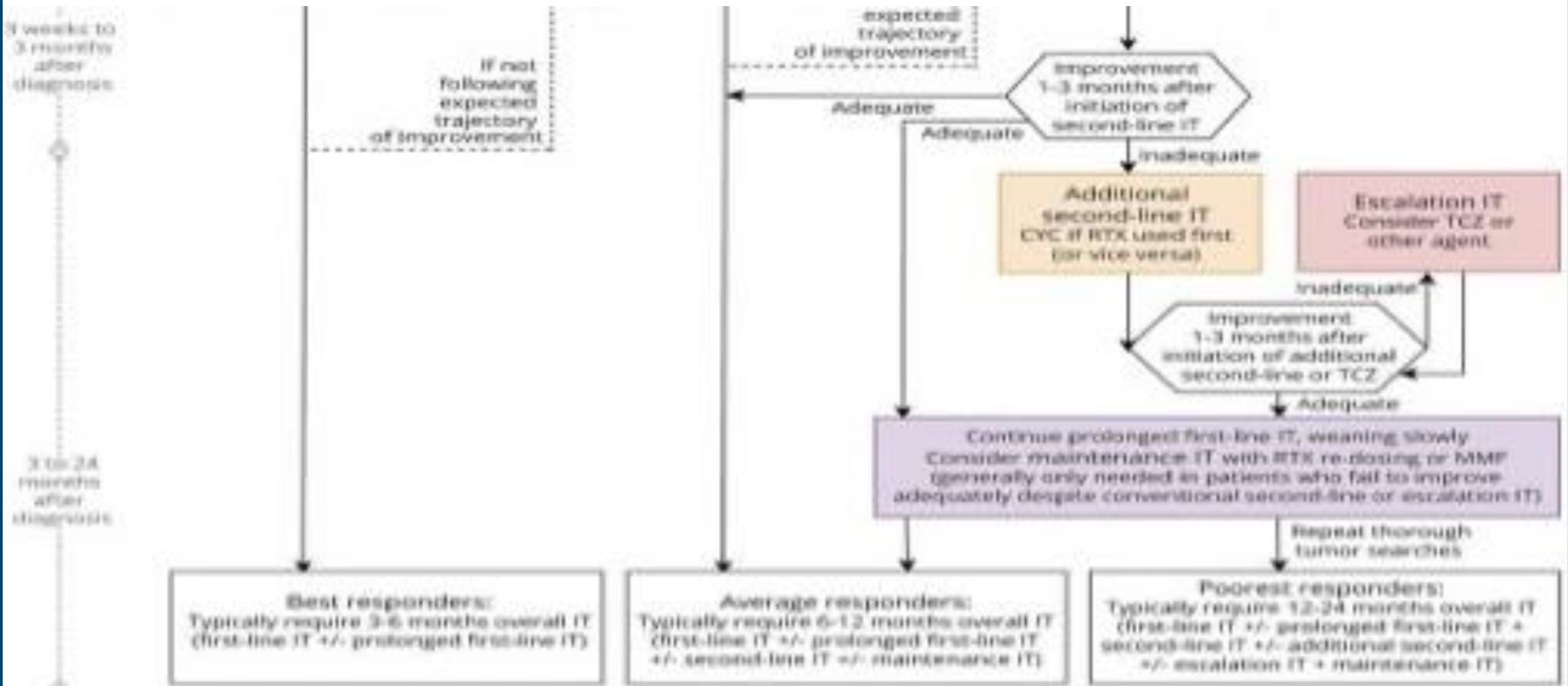
# Evaluation

- Tumor association: underlying tumor may stimulate production of anti-NMDAR antibodies
- Ovarian teratoma
  - >50% of adult females,
  - 30% of girls 14-18 yrs,
  - <10% of girls under 14 yrs
- If present complete resection necessary for maximal recovery
- All female patients require MRI abdomen/pelvis

# Treatment

- Tumor removal if present
- Prompt immunotherapy
- First line: high dose IV corticosteroids, IVIg, plasma exchange or combination
- Up to 35% don't respond
- Second line: rituximab, cyclophosphamide

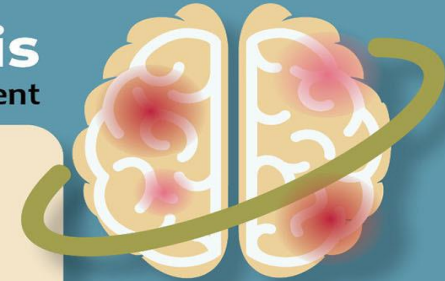




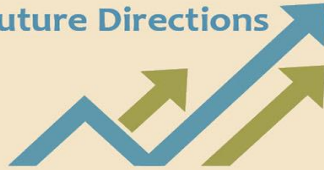
# Pediatric Autoimmune Encephalitis

Developing international consensus for diagnosis, assessments & treatment



## Future Directions



1. Developing standardized clinical pathways
2. Multidisciplinary provider education for recognition of catatonia
3. Developing standardized auto-antibody panels
4. Developing standardized imaging approaches for assessment
5. Increasing access to ECT for pediatric patients
6. Randomized controlled trials to determine efficacy of 3rd line therapies
7. Additional research on the work-up for organic causes of psychosis



### USA: Tennessee & North Carolina

#### Institution specific work-up

- serum labs
- EEG, MRI
- CSF labs
- PET *infrequently used*



### Canada: Edmonton, Alberta

#### Institution specific work-up

- serum labs
- EEG, MRI
- CSF labs
- PET *commonly used*



### Europe: France & Italy

#### Institution specific work-up

- serum labs
- EEG, MRI
- CSF labs
- PET *commonly used*

#### 1st Line Treatments

IVIG  
IV Steroids  
PX usually for ICU patients

IVIG  
IV Steroids  
PX usually for ICU patients

IVIG  
IV Steroids  
PX *if catatonia present (France only)*

#### 2nd Line Treatments

RTX *frequently used*  
CYC *infrequently used*  
MYC

RTX  
CYC *rarely used*  
MYC

RTX *if NMDA antibody+*  
CYC *widely used*  
MYC or AZA *(after CYC pulses)*

#### ECT used in treatment-resistant or malignant catatonia

#### BARRIERS TO CARE

1. Lack of consensus regarding standard of care leads to high work burden when pursuing insurance prior authorizations
2. Access to ECT varies between programs/states
3. Limited inpatient Med/Psych beds for patients with high medical complexity

1. Limited panel of auto-antibodies at local laboratory
2. Rigorous approval process for biological treatments secondary to funding
3. Lack of consensus on treatment initiation for possible AE when presenting with predominantly psychiatric symptoms

1. Limited number of specialized labs for auto-antibody testing
2. Limited access to pediatric ECT

Note: Items in red represent key differences between programs

Disclaimer: This figure is meant to demonstrate differences between international treatment approaches and should not be used to determine clinical care decisions.

Figure design by: Vladimir Ferrafiat, Genalynne Mooneyham, Kathleen Samiy

Contributing authors: Erin Stolte, Catherine Fuchs, David Cohen

v 12.4.2020

# Psychiatric symptom management: general pearls

- Immunomodulation treatment should be given prior to antipsychotics (typical or atypical)
- Elevated CK and some increased tone may be present prior to addition of psychotropic
- Benzodiazepines in escalating doses may be initially helpful for agitation
- Antipsychotic use after immune modulation may be helpful

# Psychiatric symptom management

- Insomnia: as a feature of delirium and agitation (case studies)
- Benzodiazepines, mirtazapine, trazodone, dexmedetomidine, clonidine, propofol, valproic acid use described
- Literature primarily case reports

# Psychiatric symptom management: Delirium and catatonia

- Restlessness, altered sensorium with waxing/waning course present
- Use of antipsychotics problematic and known to exacerbate catatonia
- Benzodiazepines treat catatonia but may exacerbate delirium
- Immune modulating therapies may lead to improvement or full resolution of psychosis, agitation, catatonia, delirium

# Residual psychiatric symptoms: post-inflammatory phase

- Anxiety
- Inattention
- Impulsivity
- Psychosis
- Depression
- Obsessive compulsive symptoms
- Panic

## Residual psychiatric symptoms: post-inflammatory phase

- Usual treatment algorithms may be considered if dysautonomia is resolved
  - SSRI, SNRI, TCA
  - Antipsychotics (typical and atypical)
  - Meds not tolerated during acute inflammatory phase may be helpful in post inflammatory phase
  - Ongoing surveillance for flairs, relapse is helpful
  - Awareness of where patient is in treatment course, related to infusions of immune modulators

## Questions in psychiatry clinic

- Who is on your treatment team?
  - Neurology, rheumatology, immunology, primary care?
- What is your current infusion or immunomodulatory regimen?
  - IV steroids, oral steroids, B cell modulating agents, T cell modulating agents, plasmapheresis, IVIG
- When was your last infusion or treatment?
  - Ask for specific dates, log in clinic notes to track symptom patterns for temporality
- When is your next scheduled treatment?
  - Clarify timeline of symptoms before and after treatment prior to making medication changes

# Recovery

- Protracted
- Up to 80% substantial or full recovery
- Gradual continued improvement up to 2 years after presentation
- Clinical relapse in 25% of patients, not dependent on age of onset
- Young women recovered from Anti-NMDARE require yearly tumor surveillance
- Tumor negative patients may require maintenance immunosuppression for up to a year
- Unknown effect of long-term immunosuppression on relapse risk



## References

1. Mooneyham GC, Gallentine W, Van Mater H. Evaluation and Management of Autoimmune Encephalitis: A Clinical Overview for the Practicing Child Psychiatrist. *Child Adolesc Psychiatr Clin N Am*. 2018 Jan;27(1):37-52.
2. Mooneyham GC, Ferrafiat V, Stolte E, Fuchs DC, Cohen D. Developing Consensus in the Assessment and Treatment Pathways for Autoimmune Encephalitis in Child and Adolescent Psychiatry. *Front Psychiatry*. 2021;12:638901. Published 2021 Mar 29. doi:10.3389/fpsy.2021.638901
3. Cellucci T, Van Mater H, Graus F, Muscal E, Gallentine W, Klein-Gitelman MS, Benseler SM, Frankovich J, Gorman MP, Van Haren K, Dalmau J, Dale RC. Clinical approach to the diagnosis of autoimmune encephalitis in the pediatric patient. *Neurol Neuroimmunol Neuroinflamm*. 2020 Jan 17;7(2):e663. doi: 10.1212/NXI.0000000000000663. Erratum in: *Neurol Neuroimmunol Neuroinflamm*. 2020 Apr 15;7(4): PMID: 31953309; PMID: PMC7051207.
4. Nosadini M, Thomas T, Eyre M, Anlar B, Armangue T, Benseler SM, Cellucci T, Deiva K, Gallentine W, Gombolay G, Gorman MP, Hacoheh Y, Jiang Y, Lim BC, Muscal E, Ndondo A, Neuteboom R, Rostásy K, Sakuma H, Sharma S, Tenenbaum SN, Van Mater HA, Wells E, Wickstrom R, Yeshokumar AK, Irani SR, Dalmau J, Lim M, Dale RC. International Consensus Recommendations for the Treatment of Pediatric NMDAR Antibody Encephalitis. *Neurol Neuroimmunol Neuroinflamm*. 2021 Jul 22;8(5):e1052. doi: 10.1212/NXI.0000000000001052. PMID: 34301820; PMID: PMC8299516.
5. Hon K, Leung A K, Au C, et al. (February 12, 2021) Autoimmune Encephalitis in Children: From Suspicion to Diagnosis. *Cureus* 13(2): e13307. doi:10.7759/cureus.13307
6. Graus et al., A clinical approach to diagnosis of autoimmune encephalitis. *Lancet Neurol*, 2016, Apr;15(4):391-404